

# Lab Exercise 3

## Epithelial Tissues Connective Tissue Proper

Textbook Reference: See Chapter 4

### **What you need to be able to do on the exam after completing this lab exercise:**

- Be able to identify each type of epithelial tissue on a microscope slide (or photo) and give its location and function in the body
- Be able to identify the specified features for each epithelial tissue on a microscope slide or photo
- Be able to identify each type of connective tissue proper on a microscope slide (or photo) and give its location and function in the body
- Be able to identify the specified features for each connective tissue proper on a microscope slide or photo

NOTE: On the exam, you may be asked to give the name, location, and function of the tissues. If you miss the name of the tissue, you may also miss the location and function. Make sure you can correctly identify all 12 tissues in this lab!

## Epithelial Tissues

Epithelial tissue covers surfaces/organs, and lines cavities, organs, and tubules.

Epithelial tissue is classified by the cell shape and by the number of cell layers.

Cell Shapes:

**Squamous** cells are **flat**.

**Cuboidal** cells are **cubelike**.

**Columnar** cells are **tall and column-like**.

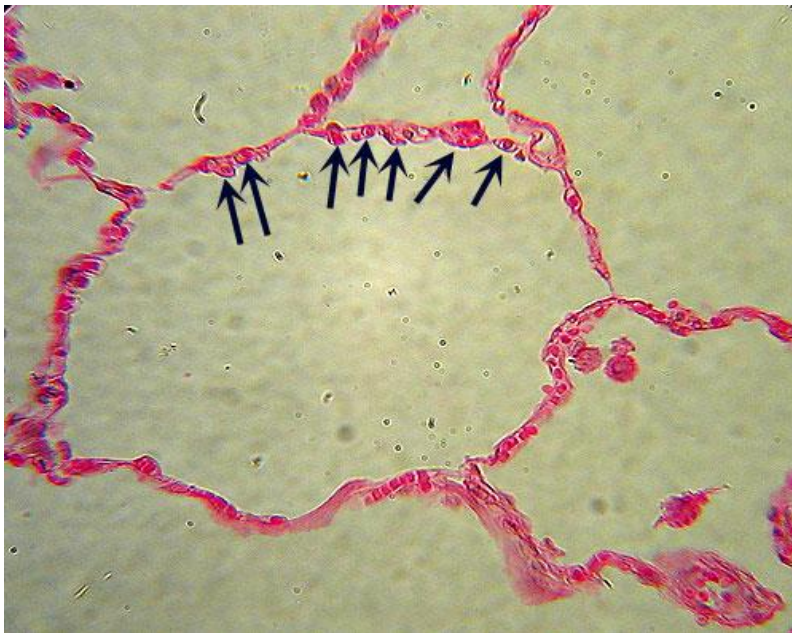Cell Layers:

**Simple** epithelial tissue has **one layer** of cells.

**Stratified** epithelial tissue has **many layers** of cells.

### Types of Epithelial Tissues

#### **Simple Squamous Epithelium**



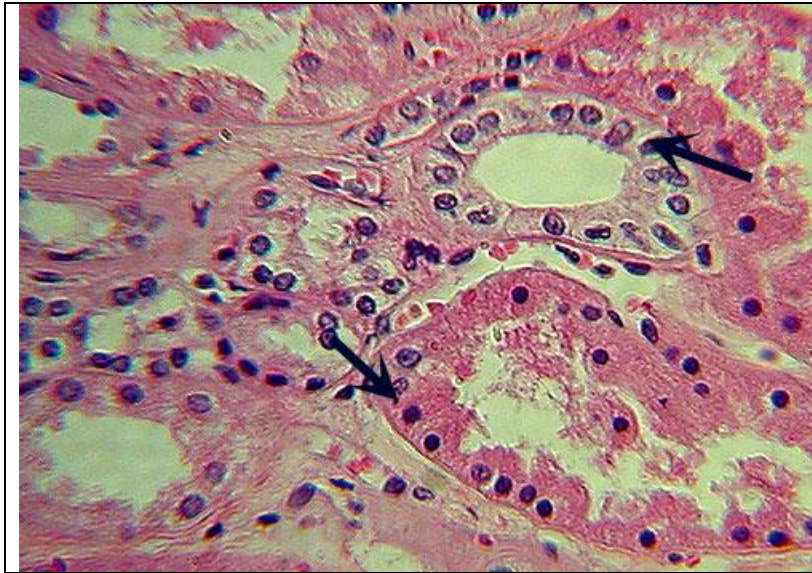
Identification: a single layer of small flat cells arranged around a large empty space

Location: lungs (lining the alveoli, or air sacs) and lining of blood vessels

Function: gas exchange (diffusion)

Features to know: nuclei

## Simple Cuboidal Epithelium



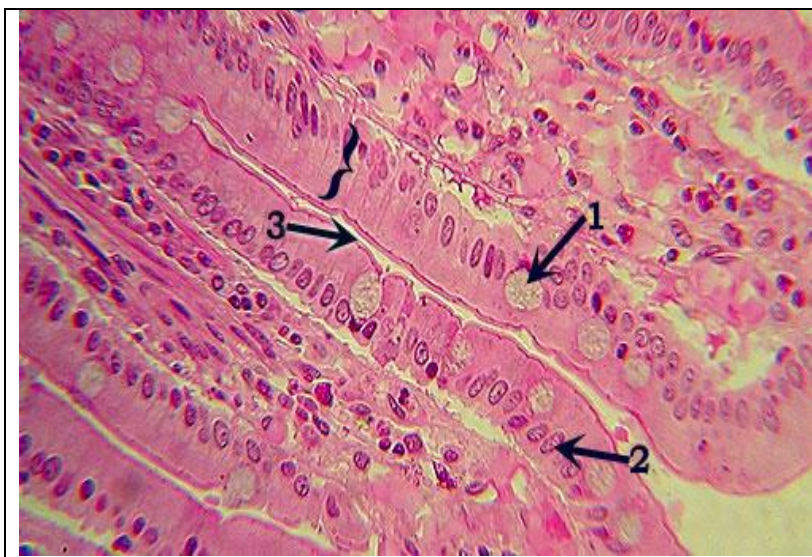Identification: a single layer of cubelike cells with large round nuclei (arrows), usually arranged in a circle (tubule)

Location: kidney tubules

Function: absorption and secretion

Features to know: nuclei

## Simple Columnar Epithelium



Identification: a single layer of tall, column-like cells with a single, neat row of oval nuclei, usually toward the base of the cell (in bracket)

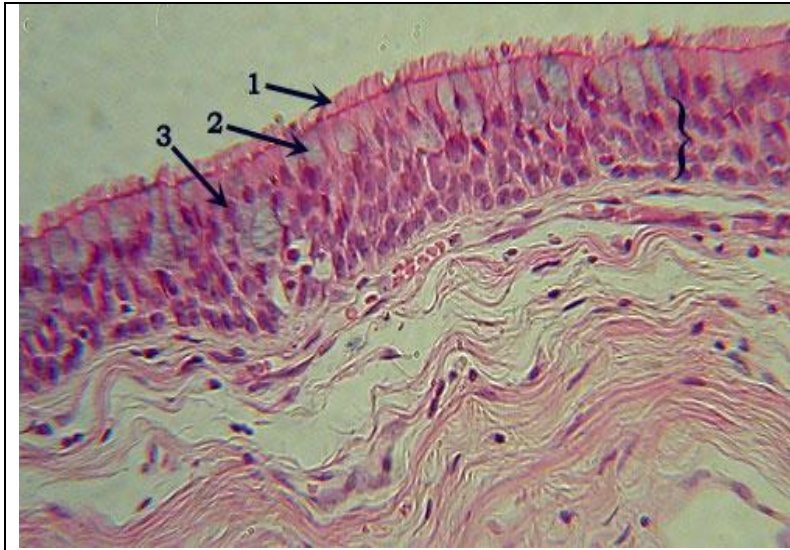
Location: jejunum of small intestine (in lining of intestine)

Function: absorption and secretion

Features to know: goblet cells (1), nuclei (2), microvilli (3)



## Pseudostratified Columnar Epithelium



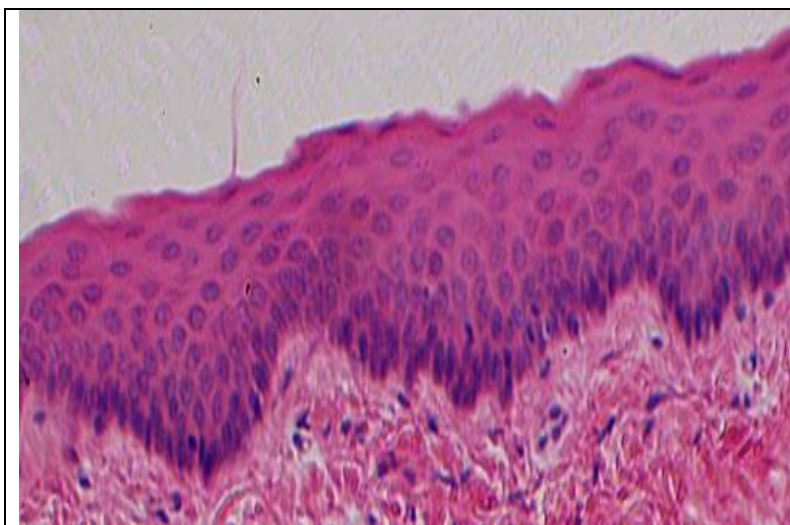
Identification: a single layer of cells of differing heights (bracketed), with nuclei in irregular “rows”, cilia cover outer surface of cells

Location: trachea (in inner lining)

Function: secretion and movement of mucus

Features to know: cilia (1), goblet cells (2), nuclei (3)

## Stratified Squamous Epithelium



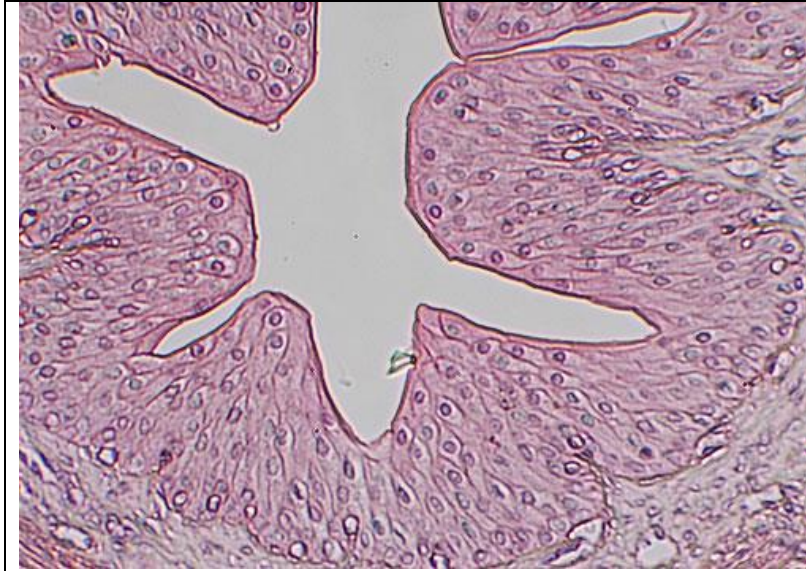Identification: many layers of cells; cells toward surface are flattened and become more cuboidal toward bottom of tissue; cells darker at bottom of tissue

Location: lining mouth and esophagus

Function: protection from abrasion and infection

Features to know: nuclei

## Transitional Epithelium



Identification: many layers of cells of varying and often irregular shape; surface in urinary bladder appears bumpy

Location: ureter and urinary bladder

Function: elasticity; stretch and recoil

Features to know: nuclei

You will NOT need to know anything about **stratified cuboidal** or **stratified columnar** epithelium in this lab.

## Identifying Epithelial Tissues Under the Microscope

Procedure:

### Simple Squamous Epithelium

1. Obtain a **simple squamous (or lung) slide** and bring into focus using the **scanning lens (4X)**. Look for flattened rings of cells around white spaces.
2. Focus on the cells, position them to the center of your field of view, and switch to the **low power lens (10X)**.
3. Focus on a few cells, position them to the center of your field of view, and switch to the **high power lens (40X)**. Notice that the cells are flattened and irregular in shape with a prominent nucleus.
4. Make a drawing of the tissue on high power in the space below. Label the nucleus.

### **Simple Cuboidal Epithelium**

1. Obtain a **simple cuboidal (kidney) slide** and bring into focus using the **scanning lens (4X)**. Look for squarish cells with dark nuclei, arranged in a circle.
2. Focus on the cells, position them to the center of your field of view, and switch to the **low power lens (10X)**.
3. Focus on a few cells, position them to the center of your field of view, and switch to the **high power lens (40X)**.
4. Make a drawing of the tissue on high power in the space below. Label the nucleus.

### **Simple Columnar Epithelium**

1. Obtain a **simple columnar (jejunum) slide** and bring into focus using the **scanning lens (4X)**. Look for column-like cells with large, dark nuclei arranged in a neat row.
2. Focus on the cells, position them to the center of your field of view, and switch to the **low power lens (10X)**.
3. Focus on a few cells, position them to the center of your field of view, and switch to the **high power lens (40X)**.
4. Make a drawing of the tissue on high power in the space below. Label the microvilli, goblet cells, and nuclei.

### **Pseudostratified Columnar Epithelium**

1. Obtain a **pseudostratified columnar (trachea) slide** and bring into focus using the **scanning lens (4X)**. Look for many dark nuclei toward the outer edge of the tissue.
2. Focus on the cells, position them to the center of your field of view, and switch to the **low power lens (10X)**.
3. Focus on a few cells, position them to the center of your field of view, and switch to the **high power lens (40X)**.
4. Make a drawing of the tissue on high power in the space below. Label the cilia, goblet cells, and nuclei.

### **Transitional Epithelium**

1. Obtain a **transitional (urinary bladder) slide** and bring into focus using the **scanning lens (4X)**. Look for many layers of cells surrounding the central white area.
2. Focus on the cells, position them to the center of your field of view, and switch to the **low power lens (10X)**.
3. Focus on a few cells, position them to the center of your field of view, and switch to the **high power lens (40X)**.
4. Make a drawing of the tissue on high power in the space below. Label the nuclei.



## Connective Tissue Proper

While epithelial tissue has a high degree of cellularity, connective tissue has more extracellular matrix between the cells.

Cells visible in connective tissue proper include:

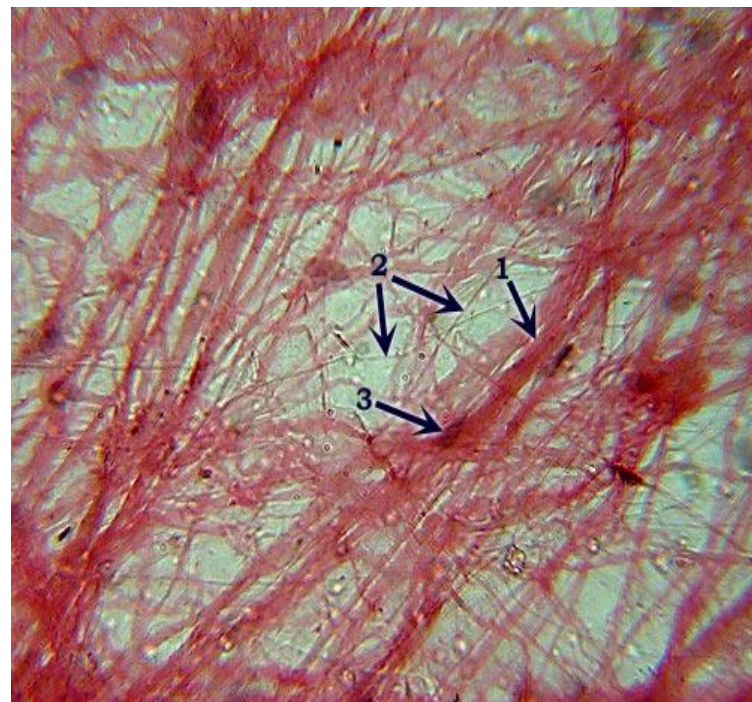
**Fibroblasts**  
**Lymphoblasts**  
**Adipocytes**

Connective tissue also consists of fibers in the matrix. The fibers found in connective tissue include:

**Collagen fibers**  
**Elastic fibers**

### Types of Connective Tissue Proper

#### **Areolar Connective Tissue**



Identification: loose arrangement of thick fibers (collagen) and thin fibers (elastic & reticular) fibers that randomly criss-cross

Location: surrounding most organs, underneath epithelia

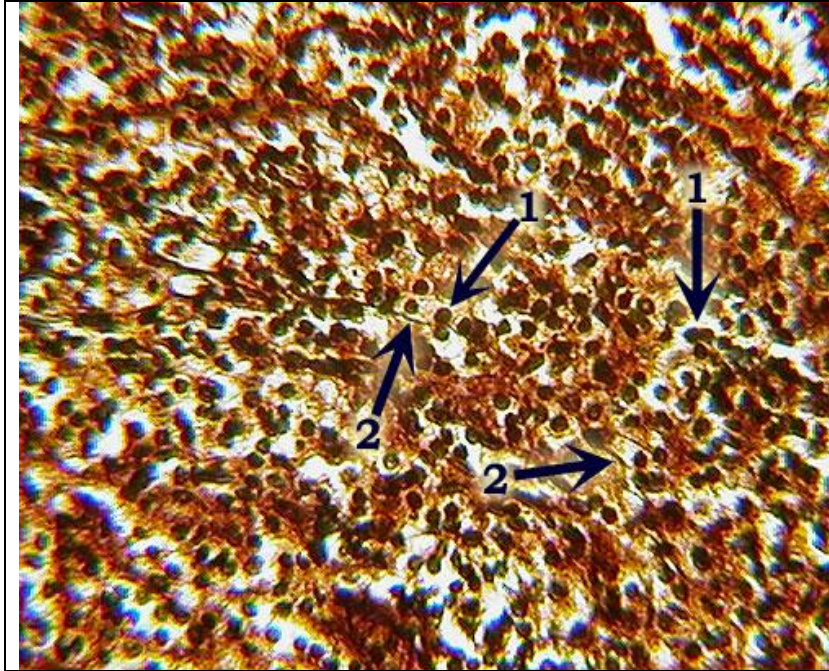
Functions: wraps, cushions, holds defensive cells, holds fluids

Fibers present: collagen fibers, elastic fibers, reticular fibers

Features to know: collagen fibers (1), elastic fibers (2), fibroblasts (3)



## Reticular Connective Tissue



Identification: dark-staining reticular fibers (2), many nuclei of lymphoblasts and other cells (1); overall brownish color is characteristic of this tissue

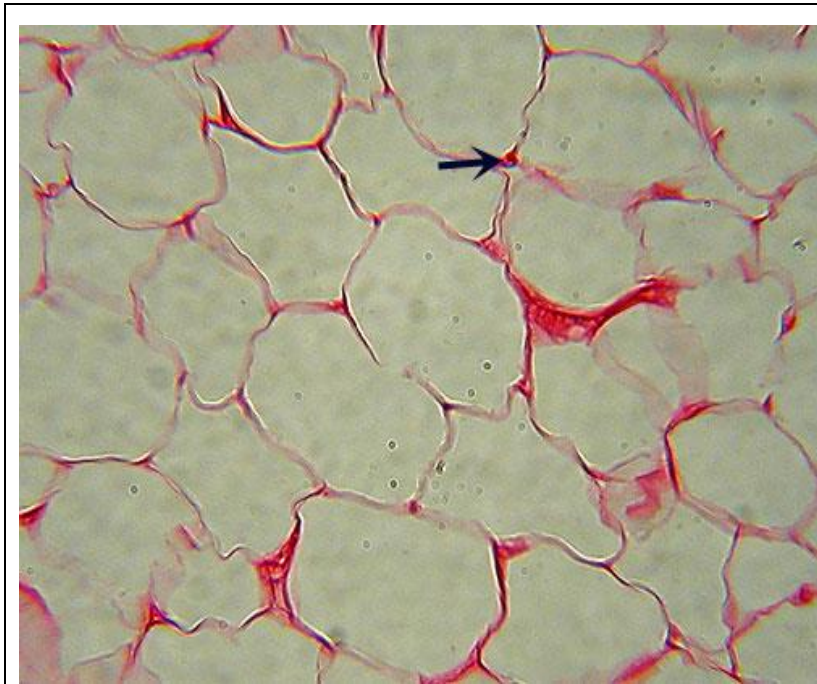
Location: spleen, bone marrow, lymph nodes

Function: forms a scaffolding to support loose tissue cells

Fibers present: reticular fibers (2)

Features to know: lymphoblasts (1)

## Adipose Connective Tissue



Identification: greatly enlarged cells, nearly the entire volume of which is a fat vacuole (white space); few nuclei will be visible

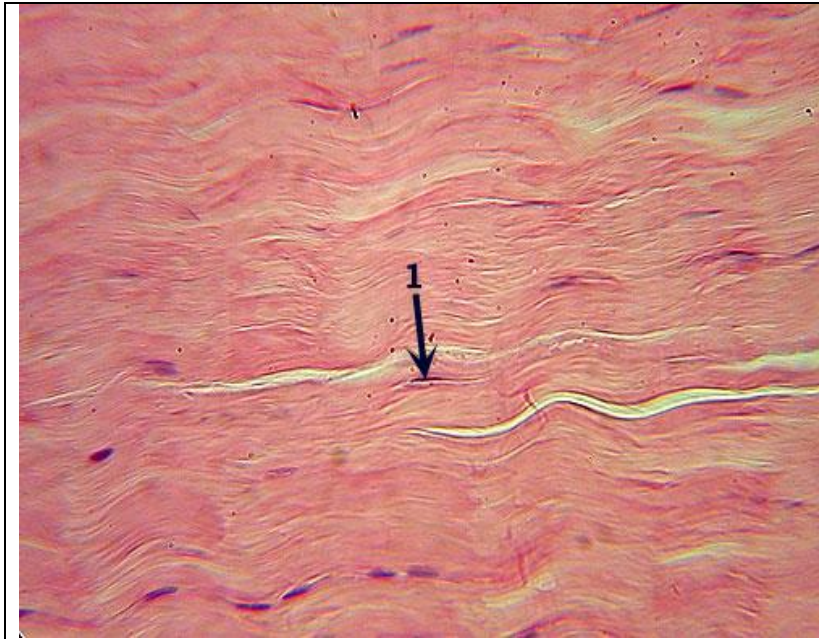Location: underneath skin, in breasts, surrounding eyes & kidneys

Functions: energy storage, cushioning, insulation

Fibers present: none visible

Features to know: adipocyte nucleus (arrow)

## Dense Regular Connective Tissue



Identification: densely packed parallel fibers with fibroblasts scattered throughout

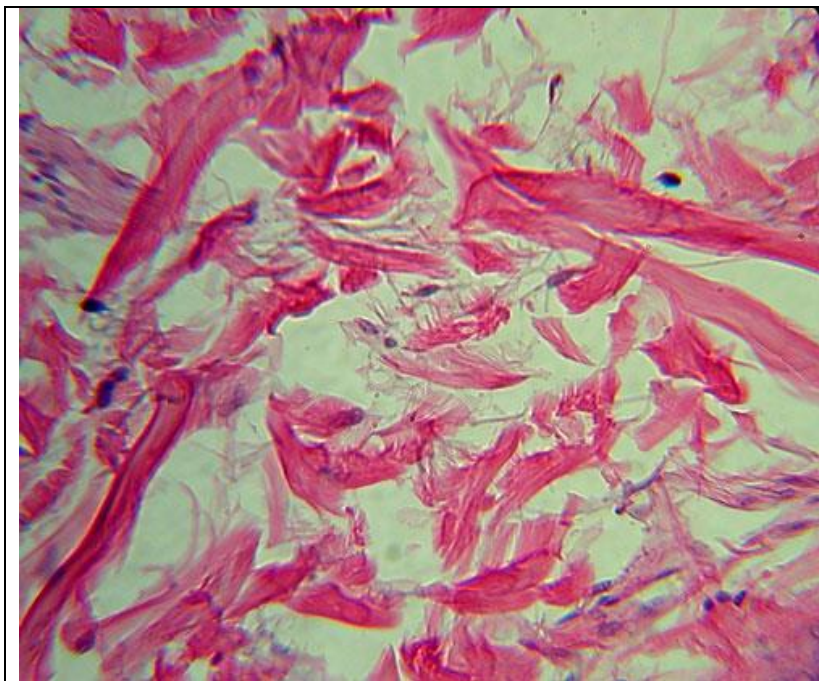
Location: ligaments and tendons

Functions: attaches bone to bone or bone to muscle; resists tensile (pulling) forces in a single direction

Fibers present: collagen fibers

Features to know: fibroblast(1)

## Dense Irregular Connective Tissue



Identification: irregular clumps of collagen fibers, separated by space; overall blotchy appearance

Location: dermis of skin

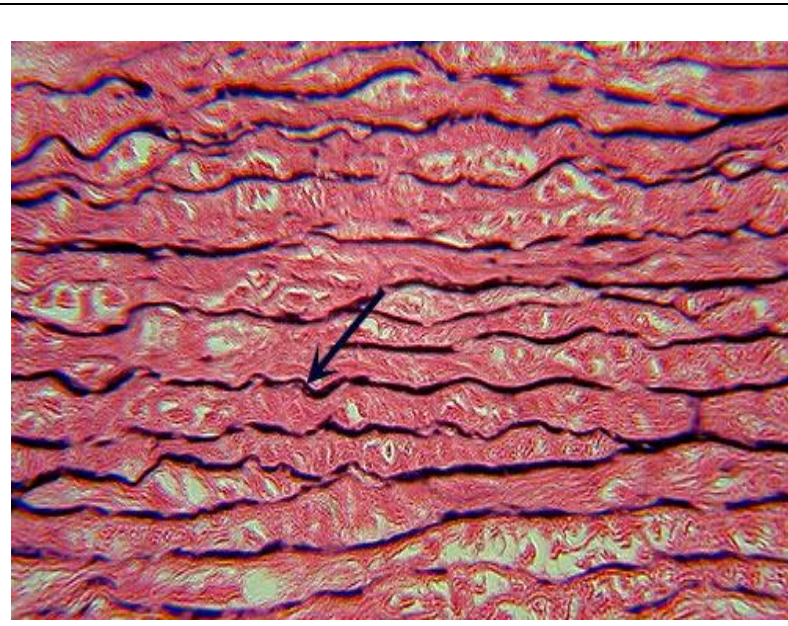Function: provides strength; can withstand tensile forces in many directions

Fibers present: collagen fibers

Features to know: fibroblasts, if visible



## Elastic Connective Tissue



Identification: densely packed collagen fibers with distinct dark, usually zigzagging lines of elastic fibers; similar to dense regular connective tissue

Location: aorta

Function: elasticity

Fibers to know: collagen fibers, elastic fibers

Features to know: fibroblasts

## Identifying Connective Tissue Proper Under the Microscope

Procedure:

### Areolar (Loose) Connective Tissue

1. Obtain an **areolar connective tissue slide** and bring into focus using the **scanning lens (4X)**. Look for criss-crossing fibers of thick and thin fibers with much space around the fibers.
2. Focus on the tissue, position it in the center of your field of view, and switch to the **low power lens (10X)**.
3. Focus on the tissue, position it in the center of your field of view, and switch to the **high power lens (40X)**.
4. Make a drawing of the tissue on high power in the space below. Label the fibroblast nuclei, collagen fibers, and elastic fibers.

### **Reticular Connective Tissue**

1. Obtain a **reticular connective tissue slide** and bring into focus using the **scanning lens (4X)**. Look for a brownish tissue with many nuclei and dark fibers.
2. Focus on the tissue, position it in the center of your field of view, and switch to the **low power lens (10X)**.
3. Focus on the tissue, position it in the center of your field of view, and switch to the **high power lens (40X)**.
4. Make a drawing of the tissue on high power in the space below. Label the fibroblast nuclei, and reticular fibers.

### **Adipose Connective Tissue**

1. Obtain an **adipose connective tissue slide** and bring into focus using the **scanning lens (4X)**. Look for thin cells surrounding a large, round fat vacuole.
2. Focus on the tissue, position it in the center of your field of view, and switch to the **low power lens (10X)**.
3. Focus on the tissue, position it in the center of your field of view, and switch to the **high power lens (40X)**.
4. Make a drawing of the tissue on high power in the space below. Label the adipocyte nuclei.



### **Dense Regular Connective Tissue**

1. Obtain a **dense regular connective tissue (tendon or ligament) slide** and bring into focus using the **scanning lens (4X)**. Look for many fibers running in the same direction.
2. Focus on the tissue, position it in the center of your field of view, and switch to the **low power lens (10X)**.
3. Focus on the tissue, position it in the center of your field of view, and switch to the **high power lens (40X)**.
4. Make a drawing of the tissue on high power in the space below. Label the fibroblast nuclei and collagen fibers.

### **Dense Irregular Connective Tissue**

1. Obtain a **dense irregular connective tissue (skin) slide** and bring into focus using the **scanning lens (4X)**. Look for scattered patches of collagen fibers.
2. Focus on the tissue, position it in the center of your field of view, and switch to the **low power lens (10X)**.
3. Focus on the tissue, position it in the center of your field of view, and switch to the **high power lens (40X)**.
4. Make a drawing of the tissue on high power in the space below. Label the fibroblast nuclei and collagen fibers.

## Elastic Connective Tissue

1. Obtain an **elastic connective tissue (aorta) slide** and bring into focus using the **scanning lens (4X)**. Look for the dark-stained elastic fibers.
2. Focus on the tissue, position it in the center of your field of view, and switch to the **low power lens (10X)**.
3. Focus on the tissue, position it in the center of your field of view, and switch to the **high power lens (40X)**.
4. Make a drawing of the tissue on high power in the space below. Label the fibroblast nuclei and elastic fibers.